

LECTURES ON NASAL OBSTRUCTION

Published @ 2017 Trieste Publishing Pty Ltd

ISBN 9780649485901

Lectures on Nasal Obstruction by A. Marmaduke Sheild

Except for use in any review, the reproduction or utilisation of this work in whole or in part in any form by any electronic, mechanical or other means, now known or hereafter invented, including xerography, photocopying and recording, or in any information storage or retrieval system, is forbidden without the permission of the publisher, Trieste Publishing Pty Ltd, PO Box 1576 Collingwood, Victoria 3066 Australia.

All rights reserved.

Edited by Trieste Publishing Pty Ltd.
Cover @ 2017

This book is sold subject to the condition that it shall not, by way of trade or otherwise, be lent, re-sold, hired out, or otherwise circulated without the publisher's prior consent in any form or binding or cover other than that in which it is published and without a similar condition including this condition being imposed on the subsequent purchaser.

www.triestepublishing.com

A. MARMADUKE SHEILD

**LECTURES ON
NASAL
OBSTRUCTION**

NASAL OBSTRUCTION.

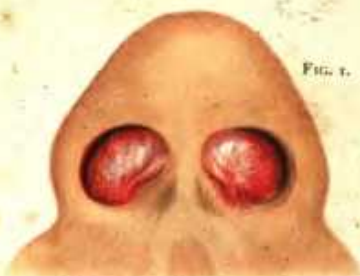

FIG. 1.

Haematoma of the Septum, which appeared immediately after a blow on the nose, and disappeared spontaneously in two months. It had been diagnosed as Sarcoma.

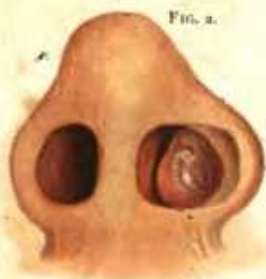

FIG. 2.

Hypertrophy of the Anterior Extremity of the Turbinal. The base is broad, and the swelling is not mobile.

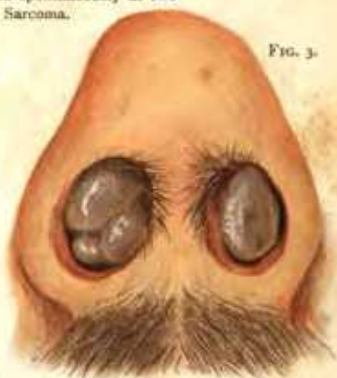


FIG. 3.

Bilateral Nasal Polypi. The grey gelatinous aspect is well shown.

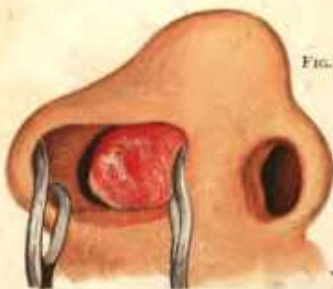


FIG. 4.

Cartilaginous outgrowth from septum nasi. The cartilage shows white on the surface, and the arborescent vessels of the mucous membrane are clearly to be seen.

LECTURES
ON
NASAL OBSTRUCTION

BY
A. MARMADUKE SHEILD

M.B. (CAMB.), F.R.C.S. (ENGL.)

*Surgeon to St. George's Hospital, London, and Surgeon in charge of the Throat Department;
Late Assistant Surgeon, Lecturer on Operative Surgery, and Aural
Surgeon, Charing Cross Hospital*

WITH ONE COLOURED PLATE AND 27 ILLUSTRATIONS IN THE TEXT



LONDON
REBMAN, LIMITED
127 SHAFTESBURY AVENUE, W.C.
1900

20. G. 53.

BOSTON MEDICAL LIBRARY
IN THE
FRANCIS A. COUNTWAY
LIBRARY OF MEDICINE



PREFACE

THIS little work contains the substance of three Clinical Lectures delivered in connection with the Throat Department at St. George's Hospital in the year 1900.

The subject is a very common and important one. Patients suffering from these conditions are constantly coming before the notice of busy practitioners, who have scant leisure for studying large and comprehensive treatises. The ignoring of nasal complaints in the past has led to a kind of surgical revival, which has engendered undue zeal and frequency in operating. The opinions promulgated in these Lectures, though differing from much of the practice of the day, are the result of personal observation and the experience of a large number of cases. Estimation of the necessity for operating is carefully discussed. Space will not permit of the full discussion of a matter which I feel is urgently in need of further surgical investigation, the diagnosis and effective treatment of sinus suppuration in association with polypi.

The coloured plates were executed from cases under

my care by Mr. Head. I am indebted for the figures to my friend Mr. J. P. L. Mummery, F.R.C.S., while Mr. H. G. Drake-Brockman has assisted me with photographs. The instruments lent by Mr. Hawksley are only sufficient in number to illustrate the text. A complete set of all the instruments and apparatus in use for these cases can only be appropriately depicted in a catalogue. It is hoped that what is said in the Lectures, will serve as a guide to the student and junior practitioner, in the recognition and treatment of the common forms of nasal obstruction likely to be met with in the daily routine of practice.

A. MARMADUKE SHEILD,
M.B., F.R.C.S.

4 CAVENDISH PLACE, W.

LIST OF ILLUSTRATIONS

COLOURED PLATE TO FACE TITLE—

FIG.

1. Hæmatoma of the Septum.
2. Hypertrophy of the Anterior Extremity of the Turbinal.
3. Bilateral Nasal Polypi.
4. Cartilaginous Outgrowth from Septum Nasi.

DRAWINGS IN TEXT—

FIG.	PAGE
1. Schoolboy with Adenoid Growths - - - -	10
2. Nasal Speculum - - - - -	11
3. Rhinoscopic Mirror - - - - -	12
4. Hook for drawing forward Soft Palate - - - -	13
5. Curved Probes for Nasal Examination - - - -	18
6. Extreme Deviation of Septum Nasi from a Neglected Fracture	19
7. Bony Cyst of the Septum Nasi, entirely occluding the Passage	21
8. Angular Deformity of Septum. Line of Section - -	43
9. Fine Saws for removing Bony Outgrowths - - -	44
10. Asch's Scissors and Flat Septal Forceps - - -	47
11. Celluloid and other Intra-nasal Splints - - -	48
12. Nasal Truss for use after Operations for Deflected Septum, with External Deformity - - - - -	48

13. Ring-Knife for the Removal of Turbinals	- - -	52
14. Ring-Knife in Position for the Removal of an Enlarged Turbinal	- - -	53
15. Écraseur Snare for Removal of Posterior Turbinal Hypertrophy	- - -	54
16. Turbinal Hypertrophy engaged in the Snare	- - -	55
17. The Side Position for Adenoid Operations, with Mason's Gag inserted	- - - - -	66
18. Steel Nail, Currettes, and Forceps for Adenoid Operations	- - -	68
19. Mass of Adenoid Growth attacked by Gottstein's Knife	- - -	69
20. A Convenient Form of Polypus Snare	- - -	84
21. A Fibro-myxomatous Polypus of the Naso-Pharynx	- - -	90
22. A Small Lobulated Polypus in the Posterior Nares	- - -	90
23. Snaring a Polypus in the Naso-Pharynx	- - -	92
24. Removal of a Naso-pharyngeal Growth with Forceps	- - -	94
25. Nasal Polypi	- - - - -	97
26. Myxo-fibromatous Tumour	- - - - -	97
27. Sarcomatous Nasal Growth, infiltrating the right Cheek, in a Myxœdematous Idiot	- - - - -	100