

**A HANDBOOK OF
VERTEBRATE DISSECTION.
PART III. HOW TO DISSECT A
RODENT, 1895, PP. 169-247**

Published @ 2017 Trieste Publishing Pty Ltd

ISBN 9780649410828

A Handbook of Vertebrate Dissection. Part III. How to Dissect a Rodent, 1895, pp. 169-247 by
H. Newell Martin & Willam A. Moale

Except for use in any review, the reproduction or utilisation of this work in whole or in part in any form by any electronic, mechanical or other means, now known or hereafter invented, including xerography, photocopying and recording, or in any information storage or retrieval system, is forbidden without the permission of the publisher, Trieste Publishing Pty Ltd, PO Box 1576 Collingwood, Victoria 3066 Australia.

All rights reserved.

Edited by Trieste Publishing Pty Ltd.
Cover @ 2017

This book is sold subject to the condition that it shall not, by way of trade or otherwise, be lent, re-sold, hired out, or otherwise circulated without the publisher's prior consent in any form or binding or cover other than that in which it is published and without a similar condition including this condition being imposed on the subsequent purchaser.

www.triestepublishing.com

H. NEWELL MARTIN & WILLAM A. MOALE

**A HANDBOOK OF
VERTEBRATE DISSECTION.
PART III. HOW TO DISSECT A
RODENT, 1895, PP. 169-247**

HANDBOOK
OF
VERTEBRATE DISSECTION



HANDBOOK
OF
VERTEBRATE DISSÉCTION.

BY
H. NEWELL MARTIN, D.Sc., M.D., M.A.,
PROFESSOR IN THE JOHNS HOPKINS UNIVERSITY,

AND
WILLIAM A. MOALE, M.D.

PART III.
HOW TO DISSECT A RODENT.

NEW YORK:
MACMILLAN AND CO.
AND LONDON.

1895.
S

RICHARD CLAY AND SONS, LIMITED,
LONDON AND BUNGAY.

YSAARLJ EMA

138
Pt. 3
1895

DESCRIPTION OF THE FIGURES.

FIG. 1, represents the roof of the skull; FIG. 2, its base; FIG. 3, the skull as seen from the left side; FIG. 4, the inner side of the right half; FIG. 5, its posterior aspect; FIG. 6, is a diagram showing the relative positions of the bones of the skull.

The references to the figures of the skull are as follows: 1, the nasals; 2, the premaxillæ; 3, the maxillæ; 4, the jugal; 5, the frontal; 6, the squamosal; 7, the parietal; 8, the inter-parietal; 9, the occipital; 10, the palatine; 11, the sphenoid; 12, the presphenoid; 13, the ethmoid; 14, the lachrymal; 15, the tympanic bulla; 16, the periotic capsule; 17, the opening of the posterior nares; 18, the opening of the left anterior naris; 19, the prepalatine and postpalatine foramina; 20, the foramen for the inferior maxillary division of fifth nerve; 21, the jugular foramen; 22, the foramen lacerum posterius; 23, the condyloid foramen; 24, the occipital condyle; 25, the paroccipital process; 26, superior process of occipital; 27, the molars; 28, the incisors; 29, the infra-orbital fissure; 30, the foramen magnum; 31, the vomer; 32, the optic foramen; 33, the foramen for the seventh nerve; 34, cavity for flocculus; 35, the carotid foramen; 36, foramen between the pterygoid processes; 37, the opening of the external auditory meatus; 38, foramen for nasal branch of the fifth nerve.

43473

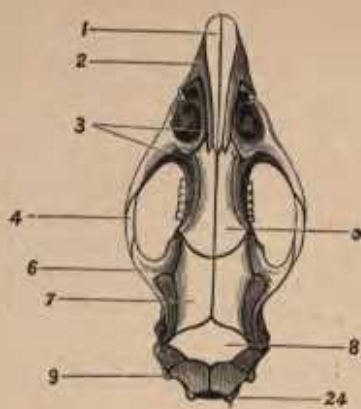


Figure 1.

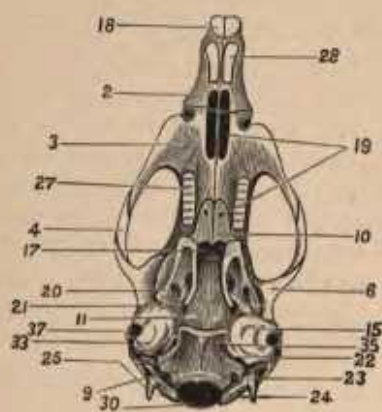


Figure 2.

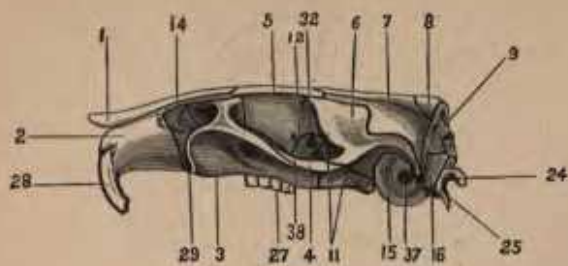


Figure 3.

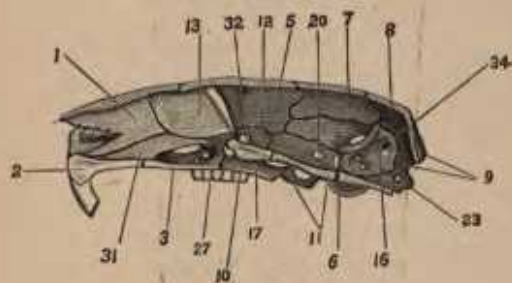


Figure 4.

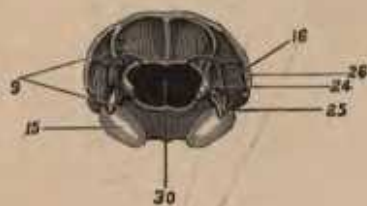


Figure 5.