

**THE TONSILS, FAUCIAL,
LINGUAL, AND PHARYNGEAL,
WITH SOME ACCOUNT OF THE
POSTERIOR AND LATERAL
PHARYNGEAL NODULES**

Published @ 2017 Trieste Publishing Pty Ltd

ISBN 9780649087761

The tonsils, faucial, lingual, and pharyngeal, with some account of the posterior and lateral pharyngeal nodules by Harry A. Barnes

Except for use in any review, the reproduction or utilisation of this work in whole or in part in any form by any electronic, mechanical or other means, now known or hereafter invented, including xerography, photocopying and recording, or in any information storage or retrieval system, is forbidden without the permission of the publisher, Trieste Publishing Pty Ltd, PO Box 1576 Collingwood, Victoria 3066 Australia.

All rights reserved.

Edited by Trieste Publishing Pty Ltd.
Cover @ 2017


This book is sold subject to the condition that it shall not, by way of trade or otherwise, be lent, re-sold, hired out, or otherwise circulated without the publisher's prior consent in any form or binding or cover other than that in which it is published and without a similar condition including this condition being imposed on the subsequent purchaser.


www.triestepublishing.com

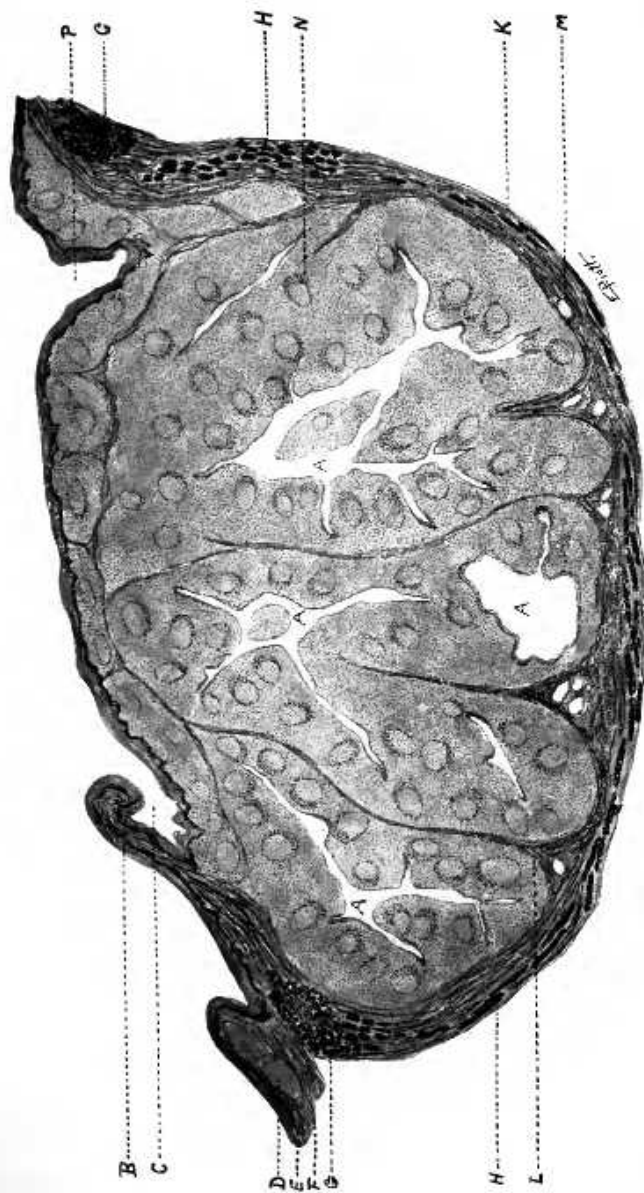
HARRY A. BARNES

**THE TONSILS, FAUCIAL,
LINGUAL, AND PHARYNGEAL,
WITH SOME ACCOUNT OF THE
POSTERIOR AND LATERAL
PHARYNGEAL NODULES**

THE TONSILS







Cross-section of human tonsil, age eleven years, dissected out in capsule. X 10. This tonsil was moderately hypertrophied, with crypts greatly dilated and filled with detritus. It represents a condition found in a large percentage of the hypertrophied tonsils of childhood.

A, Crypts, very irregular and dilated; B, Plica triangularis; C, Anterior fossa; D, Lymphoid follicles outside capsule; E, Surface epithelium; F, Tunica propria of surface mucosa; G, Mucous glands; H, Mucous fibers of capsule; K, Capsule; L, Trabecula; M, Blood vessel; N, Lymphoid follicle with germinal center; P, Posterior fossa.

8-1125
B

LIBRARY

THE TONSILS

FAUCIAL, LINGUAL, AND PHARYNGEAL

WITH SOME ACCOUNT OF THE POSTERIOR AND
LATERAL PHARYNGEAL NODULES.

BY
HARRY A. BARNES, M.D.

INSTRUCTOR IN LARYNGOLOGY, HARVARD MEDICAL SCHOOL; SURGEON IN
THE DEPARTMENT FOR DISEASES OF THE NOSE AND THROAT, BOSTON
DISPENSARY; ASSISTANT LARYNGOLOGIST, MASSACHUSETTS GEN-
ERAL HOSPITAL; MEMBER NEW ENGLAND LARYNGOLOGICAL
AND OTOLOGICAL SOCIETY; MEMBER AMERICAN LARYN-
GOLOGICAL, RHINOLOGICAL AND OTOLOGICAL SOCIETY.

ILLUSTRATED

ST. LOUIS
C. V. MOSBY COMPANY
1916

146091
27/5/18

COPYRIGHT, 1914, BY C. V. MOSBY COMPANY

Press of
C. V. Mosby Company
St. Louis

TO
WILLIAM THOMAS COUNCILMAN, A.M., M.D., LL.D.,
SHATTUCK PROFESSOR OF PATHOLOGICAL ANATOMY,
MEDICAL SCHOOL OF HARVARD UNIVERSITY,
WHO INITIATED ME INTO THE STUDY OF THE LYMPHOID TISSUES
THIS BOOK IS RESPECTFULLY INSCRIBED.