

**A CLINICAL TREATISE ON
DISEASES OF THE LIVER. IN
THREE VOLUMES. VOL. II**

Published @ 2017 Trieste Publishing Pty Ltd

ISBN 9780649035687

A Clinical Treatise on Diseases of the Liver. In Three Volumes. Vol. II by Fried. Theodor Frerichs

Except for use in any review, the reproduction or utilisation of this work in whole or in part in any form by any electronic, mechanical or other means, now known or hereafter invented, including xerography, photocopying and recording, or in any information storage or retrieval system, is forbidden without the permission of the publisher, Trieste Publishing Pty Ltd, PO Box 1576 Collingwood, Victoria 3066 Australia.

All rights reserved.

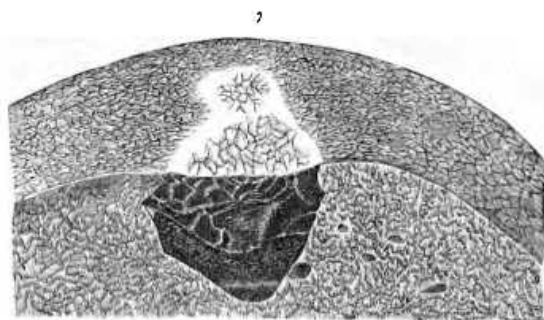


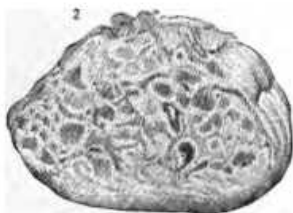
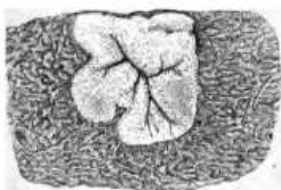
Edited by Trieste Publishing Pty Ltd.
Cover @ 2017

This book is sold subject to the condition that it shall not, by way of trade or otherwise, be lent, re-sold, hired out, or otherwise circulated without the publisher's prior consent in any form or binding or cover other than that in which it is published and without a similar condition including this condition being imposed on the subsequent purchaser.

www.triestepublishing.com

FRIED. THEODOR FRERICHS

**A CLINICAL TREATISE ON
DISEASES OF THE LIVER. IN
THREE VOLUMES. VOL. II**



A

CLINICAL TREATISE

ON

*Robert W. Muller, M.D.
N. Y. City.*

DISEASES OF THE LIVER.

BY

DR. FRIED. THEOD. EBERICH.

PROFESSOR OF CLINICAL MEDICINE IN THE UNIVERSITY OF BERLIN, ETC.:

MEDICAL PRIVY-COUNSELLOR AND MEDICAL ADVISER TO THE MINISTRY OF PUBLIC INSTRUCTION
AND MEDICINE IN BERLIN.

IN THREE VOLUMES.

VOL. II.

TRANSLATED BY

CHARLES MURCHISON, M.D., F.R.C.P.,

PHYSICIAN TO THE LONDON FEVER HOSPITAL, LECTURER ON PATHOLOGICAL ANATOMY, AND
ASSISTANT-PHYSICIAN AT THE MIDDLESEX HOSPITAL.



NEW YORK:

WM. WOOD & CO., 27 GREAT JONES STREET.

1879.

B

LIBRARY

F88m
v. 2
1879

EXPLANATION OF FRONTISPIECE.

Fig. 1. Syphilitic fibroid nodule of liver. (See p. 161.)—Circumscribed yellowish-white infiltration, from the liver of a syphilitic patient. The abnormal deposit is situated at the periphery of the organ, where it is sharply defined from the surrounding hyperæmic tissue. It is of firm consistence and consists of connective tissue infiltrated with a crumbling amorphous material, nuclei and oil-globules. In the centre of the nodule are the ramifications of the penetrating blood-vessels, and close to them are some soft yellowish-green places.

Fig. 2. Alveolar cancer of the liver. (See Vol. III., p. 51.)—*a.* Serous investment of outer surface. *b.* Under surface. *c.* The morbid growth growing from the upper surface of the liver.

Figs. 3, 4, 5, and 6. Hepatic cells in a state of waxy or amyloid degeneration. (See p. 173.) Fig. 3. A group of hepatic cells, in which the different stages of the deposit of amyloid matter may be traced.—*a.* A cell with a distended nucleus; *b.* An enlarged cell, uniformly filled; the nucleus is no longer visible; *c.* Crushed débris of cells. Fig. 4. Change of color in the cells produced by the addition of solution of iodine. Fig. 5. The same after the addition of solution of iodine and sulphuric acid. Fig. 6. A firm aggregation of hepatic cells colored by solution of iodine.

Fig. 7. Cavernous tumor of the liver. (See Vol. III., p. 1.)—Portion of the right lobe of the liver, showing a cavernous tumor (Telangiectasis) with sharply defined margins, penetrating in a wedge-shaped form, from the outer surface into the parenchyma, of the natural size.

	PAGE
Treatment	48
Hyperæmia of the liver in scurvy	49
d. Hyperæmia of the liver resulting from the suppression of habitual hæmorrhages, &c.	49
Hepatic hæmorrhage, apoplexy, and hæmorrhagic softening of the liver.	50

CHAPTER III.

INFLAMMATION OF THE LIVER. ITS VARIOUS FORMS AND CONSEQUENCES.	54
Historical account.	54
I. Inflammation of the capsule of the liver.—Peri-hepatitis.	56
1. Its nature.	56
2. Causes and consequences.	56
3. Symptoms.	58
4. Treatment.	59
II. Inflammation of the hepatic parenchyma.	59
A. Diffuse hepatitis.	59
a. The acute form.	59
Illustrative Cases.	60
b. Chronic interstitial form.—Cirrhosis of the liver.	68
1. Historical account.	68
2. Anatomical description.	70
Characters of the secreting tissue.	72
“ of the connective tissue.	73
“ of the vascular apparatus.	73
“ of the bile-ducts.	74
3. Etiology.	74
Granulations produced by fatty degeneration.	75
“ produced by hyperæmia from obstructed circulation.	75
“ produced by pylephlebitis adhesiva.	75
“ produced by morbid state of bile-ducts.	76
Abuse of spirits.	76
Constitutional syphilis and intermittent fever.	77
Age, sex, &c.	78
4. Symptoms.	78
A. General clinical history.	78
B. Local symptoms.	79
a. Characters presented by the liver.	79
Symptoms of obstructed circulation.	80
Collateral channels of circulation.	80
b. The splenic tumor.	82
c. Ascites.	83
d. Functions of the stomach and intestinal canal.	84
c. Alterations of nutrition and other consecutive disorders.	86
5. Complications.	88
6. Duration and progress.	89
7. Modes of termination.	89
8. Prognosis.	90
9. Diagnosis.	90
10. Varieties and illustrative cases.	91
Simple forms.	92
Cirrhosis after intermittent fever.	97
“ after syphilis.	103
Complication with waxy liver.	103
Influence of chronic peritonitis in giving rise to cirrhosis.	111
11. Treatment.	118
Simple induration of the liver.	121
Case in illustration.	122
B. Circumscribed inflammation and abscess of the liver.	125
1. Anatomical description.	125
Lesions of other organs in connection with it.	129
2. Etiology.	130