

# **THE DIAGNOSIS AND TREATMENT OF CHRONIC NASAL CATARRH**

Published @ 2017 Trieste Publishing Pty Ltd

ISBN 9780649279678

The Diagnosis and treatment of chronic nasal catarrh by George Morewood Lefferts

Except for use in any review, the reproduction or utilisation of this work in whole or in part in any form by any electronic, mechanical or other means, now known or hereafter invented, including xerography, photocopying and recording, or in any information storage or retrieval system, is forbidden without the permission of the publisher, Trieste Publishing Pty Ltd, PO Box 1576 Collingwood, Victoria 3066 Australia.

All rights reserved.

Edited by Trieste Publishing Pty Ltd.  
Cover @ 2017

This book is sold subject to the condition that it shall not, by way of trade or otherwise, be lent, re-sold, hired out, or otherwise circulated without the publisher's prior consent in any form or binding or cover other than that in which it is published and without a similar condition including this condition being imposed on the subsequent purchaser.

[www.triestepublishing.com](http://www.triestepublishing.com)

**GEORGE MOREWOOD LEFFERTS**

**THE DIAGNOSIS AND  
TREATMENT OF CHRONIC  
NASAL CATARRH**



THE  
DIAGNOSIS AND TREATMENT  
OF  
CHRONIC NASAL CATARRH.

THREE CLINICAL LECTURES

DELIVERED AT THE COLLEGE OF PHYSICIANS AND SURGEONS,  
NEW YORK.

BY

GEORGE MOREWOOD LEFFERTS, A. M., M. D.,

*Clinical Professor of Laryngoscopy and Diseases of the Throat in the College of  
Physicians and Surgeons, Medical Department of Columbia College, New York.*

REPRINTED FROM THE MEDICAL NEWS OF PHILADELPHIA, APRIL 26,  
AND MAY 3, 1884, AND FROM AMERICAN CLINICAL  
LECTURES, VOL. II, NO. VI.

---

ST. LOUIS:  
LAMBERT & CO.

1884.

45

I

THE END

R361  
L99  
1884

## CHRONIC NASAL CATARRH.

### LECTURE I.

#### EXAMINATION.

GENTLEMEN: Accurate diagnosis being the corner-stone of all successful treatment, my first lecture to you of this series must necessarily deal with the methods of making a direct anterior and posterior examination of the nasal passages—in other words, the performance of anterior rhinoscopy and of posterior rhinoscopy, or, more properly, pharyngo-rhinoscopy. The importance of such an examination, as a preliminary step to all attempts at treatment, will be alluded to more than once in the following lectures.

I have been sometimes reminded that there is an idea in the minds of very many of our profession that these methods of physical examination, procedures which necessarily involve the use of special instruments, such as the rhinoscope, specula, etc., and require some practice to make perfect, demand such a high degree of skill on the part of the physician, such an amount of toleration on the part of the patient, and the use of such costly apparatus, that they are of necessity confined to the hands of a few, who have by special training learned dexterity in manipulation, and by opportunity and special study acquired the right to denominate themselves *Specialists*.

But, gentlemen, this is hardly true, for I know that by the exercise of a moderate amount of diligent practice—in other words, learning practically where and why he fails in examinations, and not relying upon his books alone for his knowledge, by perseverance in the use of the necessary instruments, directed by an intelligent appreciation of

34322

the why and wherefore of their application — the general practitioner may overcome such difficulties as stand in the way of their successful employment, and this with the simplest aids in the way of apparatus. If he will do this — and I hope to show you how he can most easily accomplish it — I assure him that the results which will be afforded, their importance and interest, and his satisfaction at having mastered the use of an invaluable diagnostic means and therapeutic aid, which to-day are beginning to be considered a very necessary part of medical practice, will most richly repay him for the time and labor which he has expended.

Certain instruments are essential for the practice of rhinoscopy, but they are few, simple, and not necessarily of great cost. They are: 1, a good artificial illumination; 2, a concave forehead reflector, and, in addition, for anterior rhinoscopy; 3, a nasal speculum, and for posterior rhinoscopy; 4, tongue spatula; and, 5, a rhinoscopic mirror. For ordinary purposes there is no better nor more convenient light than that which is furnished by the argand gas burner, mounted upon a drop light, which permits of the flame being lowered or elevated at will. Such a light is certainly easily procurable, and at a slight cost, if gas is obtainable; if not, as in the country, then the ordinary student lamp, which burns petroleum or oil, forms a very efficient substitute. To either of these lamps it is no difficult matter to attach a single plano-convex lens two and one-half inches in diameter, which fits into the metallic chimney or tube known as Mackenzie's, if you deem it desirable to intensify their illuminating powers. Such an apparatus is shown in both of the accompanying illustrations (figs. 1 and 7).

Our next essential is the forehead mirror or reflector (fig. 2). This is a slightly concave mirror, either three and one-half or four inches in diameter, with a focal distance of about twelve inches. The glass may be perforated at its center, or simply left unsilvered at that point, both plans having their advocates; the latter, I think, you will find most satisfactory, and the only objection that I have ever heard urged against it — the liability of a coating of dust gathering upon the uncovered portion and obscuring the view through it — is one that is certainly very easily obviated. How this mirror shall be worn, and how it shall be attached to the operator's head, are also points upon which there is *some difference* of opinion. Bruns, for instance, says that it should






Fig. 1. Lamp for illuminating purposes.

be worn in front of the nose and mouth. Johnson prefers to have it over the forehead, while Czermack, Mackenzie, and others, among whom I rank myself, think that it should be placed directly over one of the eyes, the right being usually preferred. There is no question but that this last method is the one that is, theoretically, correct, and it is fully as easy to acquire as the others. The physician then looks through the uncovered portion of the glass, and his eye is within the center of the cone of light which is thrown from the mirror into the patient's mouth, while at the same time his eyes are protected from its

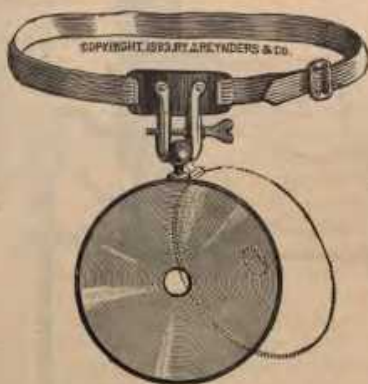

Fig. 2. Concave forehead reflector.

glare, for the rays of light from the lamp reach the mirror in an oblique direction, and do not, therefore, strike against the eye which is behind the reflector, while the other is beyond, or, rather, to one side, of their line of direction. Both eyes are then to be used in looking at the picture which is reflected in the rhinoscopic mirror.

For attaching the mirror to the head the band shown in the cut may be employed, or, still better, and as I prefer, the head-band known as *Kramer's*. A suitable dilator for the *alæ* of the nostril is usually nec-

essary, and is certainly advisable, although a fair examination of the parts may be made without it by simply elevating the tip of the nose with the thumb and dilating the nasal openings by pressure upon it. Of these nasal specula there are many kinds, and some prefer one, some another. The two best, perhaps, are those known as Robert and



Fig. 3. Robert and Collin's nasal speculum.

Collin's speculum (fig. 3), a double-bladed affair, with a broad, trumpet-shaped orifice, which is dilated and held open by means of a screw ar-



Fig. 4. Frankel's nasal speculum.

rangement upon its side, and the wire speculum (fig. 4), somewhat similar to a dilator used by oculists for separating the lids. Both these are good; the first is a favorite one with me, but I not unfrequently use an ordinary ear speculum, especially with small children, and find it answers a good purpose. Thudicum's speculum is useful for operations in the anterior nares. With these simple means alone, then — *viz.*, those thus far alluded to — you will be able to see all of the anterior nares that there is to be seen, without the use of further instrumental assistance, although many other aids have been devised, which will be found in practice more of a hindrance than a help.