

**A CLINICAL TREATISE ON
DISEASES OF THE LIVER. IN
THREE VOLUMES. VOL. II**

Published @ 2017 Trieste Publishing Pty Ltd

ISBN 9780649035670

A Clinical Treatise on Diseases of the Liver. In Three Volumes. Vol. II by Dr. Fried. Theod. Frerichs & Charles Murchison

Except for use in any review, the reproduction or utilisation of this work in whole or in part in any form by any electronic, mechanical or other means, now known or hereafter invented, including xerography, photocopying and recording, or in any information storage or retrieval system, is forbidden without the permission of the publisher, Trieste Publishing Pty Ltd, PO Box 1576 Collingwood, Victoria 3066 Australia.

All rights reserved.

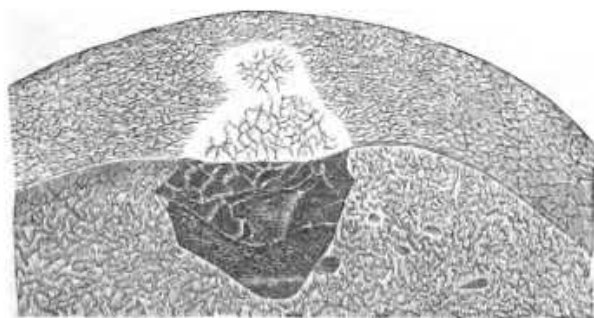
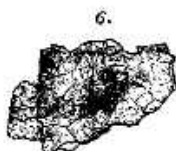
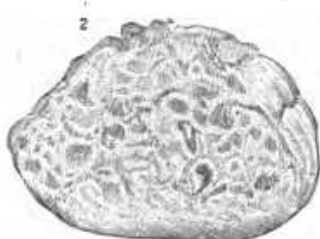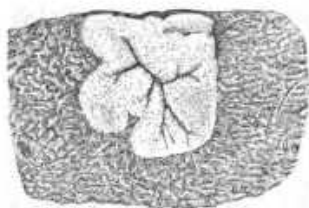
Edited by Trieste Publishing Pty Ltd.
Cover @ 2017

This book is sold subject to the condition that it shall not, by way of trade or otherwise, be lent, re-sold, hired out, or otherwise circulated without the publisher's prior consent in any form or binding or cover other than that in which it is published and without a similar condition including this condition being imposed on the subsequent purchaser.

www.triestepublishing.com

DR. FRIED. THEOD. FRERICHS & CHARLES MURCHISON

**A CLINICAL TREATISE ON
DISEASES OF THE LIVER. IN
THREE VOLUMES. VOL. II**



A
CLINICAL TREATISE
ON
DISEASES OF THE LIVER.

BY

DR. FRIED. THEOD. FRERICH'S,

PROFESSOR OF CLINICAL MEDICINE IN THE UNIVERSITY OF BERLIN, ETC.;
MEDICAL PRIVY-COUNSELLOR AND MEDICAL ADVISER TO THE MINISTRY OF PUBLIC INSTRUCTION
AND MEDICINE AT BERLIN.

IN THREE VOLUMES.

VOL. II.

TRANSLATED BY

CHARLES MURCHISON, M.D., F.R.C.P.,

PHYSICIAN TO THE LONDON FEVER HOSPITAL, LECTURER ON PATHOLOGICAL ANATOMY, AND
ASSISTANT-PHYSICIAN AT THE MIDDLESEX HOSPITAL.

NEW YORK:
WM. WOOD & CO., 27 GREAT JONES STREET.

1879.

EXPLANATION OF FRONTISPIECE.

Fig. 1. Syphilitic fibroid nodule of liver. (See p. 161.)—Circumscribed yellowish-white infiltration, from the liver of a syphilitic patient. The abnormal deposit is situated at the periphery of the organ, where it is sharply defined from the surrounding hyperæmic tissue. It is of firm consistence and consists of connective tissue infiltrated with a crumbling amorphous material, nuclei and oil-globules. In the centre of the nodule are the ramifications of the penetrating blood-vessels, and close to them are some soft yellowish-green pieces.

Fig. 2. Alveolar cancer of the liver. (See Vol. III., p. 51.)—*a.* Serous investment of outer surface. *b.* Under surface. *c.* The morbid growth growing from the upper surface of the liver.

Figs. 3, 4, 5, and 6. Hepatic cells in a state of waxy or amyloid degeneration. (See p. 173.) Fig. 3. A group of hepatic cells, in which the different stages of the deposit of amyloid matter may be traced.—*a.* A cell with a distended nucleus; *b.* An enlarged cell, uniformly filled; the nucleus is no longer visible; *c.* Crushed debris of cells. Fig. 4. Change of color in the cells produced by the addition of solution of iodine. Fig. 5. The same after the addition of solution of iodine and sulphuric acid. Fig. 6. A firm aggregation of hepatic cells colored by solution of iodine.

Fig. 7. Cavernous tumor of the liver. (See Vol. III., p. 1.)—Portion of the right lobe of the liver, showing a cavernous tumor (Telangiectasis) with sharply defined margins, penetrating in a wedge-shaped form, from the outer surface into the parenchyma, of the natural size.




TABLE OF CONTENTS.

CHAPTER I.

	PAGE
<i>The Pigment-Liver.</i>	1
I. Historical account.	1
II. Anatomy of the pigment-liver.	8
Occurrence of pigment in the spleen, brain, kidneys, and blood.	4
Place and mode of origin of the pigment	7
III. Effects of the deposit of pigment upon the structure and functions of the different organs of the body	9
Derangements in the liver	9
" in the brain	10
" in the kidneys	13
IV. Forms of fever which accompany these morbid processes.	13
Their progress	14
Account of their anatomical lesions	15
I. Forms with cerebral disturbance	15
II. Forms with predominant affection of the kidneys	21
III. Forms in which the liver and the gastro-intestinal canal are pre- eminently involved	24
V. Etiology of pigment-liver.	30
VI. Diagnosis	30
VII. Prognosis	30
VIII. Treatment	31

CHAPTER II.

<i>Hyperæmia of the liver, and its consequences.</i>	33
General observations on the conditions of the circulation of the blood in the liver.	33
A. Hyperæmia of the liver from obstructed circulation.	34
I. Pathology	34
Wasting of the liver consequent upon this	36
Its effects upon the organs included in the portal system	36
II. Symptoms	37
III. Treatment	38
Mechanical hyperæmia in consequence of constriction of the vena cava and of the hepatic veins	42
B. Congestive conditions and atonic hyperæmias of the liver.	42
a. Congestions dependent upon the processes of digestion	43
The effects of irritating ingesta upon the liver	44
Chronic hyperæmia of the liver resulting from over-feeding	44
Its treatment	45
b. Traumatic hyperæmia	46
c. Hyperæmias dependent upon the effects of high temperature and mias- matic effluvia	46
Acute and chronic forms—Their consequences	47

	PAGE
Treatment	48
Hyperæmia of the liver in scurvy.....	49
d. Hyperæmia of the liver resulting from the suppression of habitual hæmorrhages, &c.....	49
Hepatic hæmorrhage, apoplexy, and hæmorrhagic softening of the liver...	50

CHAPTER III.

INFLAMMATION OF THE LIVER. ITS VARIOUS FORMS AND CONSEQUENCES....	54
Historical account.....	54
I. Inflammation of the capsule of the liver.—Peri-hepatitis.....	56
1. Its nature.....	56
2. Causes and consequences.....	56
3. Symptoms.....	58
4. Treatment.....	59
II. Inflammation of the hepatic parenchyma.....	59
A. Diffuse hepatitis.....	59
a. The acute form.....	59
Illustrative Cases.....	60
b. Chronic interstitial form.—Cirrhosis of the liver.....	68
1. Historical account.....	68
2. Anatomical description.....	70
Characters of the secreting tissue.....	72
" of the connective tissue.....	73
" of the vascular apparatus.....	73
" of the bile-ducts.....	74
3. Etiology.....	74
Granulations produced by fatty degeneration.....	75
" produced by hyperæmia from obstructed circulation.....	75
" produced by pyelephlebitis adhesiva.....	75
" produced by morbid state of bile-ducts.....	76
Abuse of spirits.....	76
Constitutional syphilis and intermittent fever.....	77
Age, sex, &c.....	78
4. Symptoms.....	78
A. General clinical history.....	78
B. Local symptoms.....	79
a. Characters presented by the liver.....	79
Symptoms of obstructed circulation.....	80
Collateral channels of circulation.....	80
b. The splenic tumor.....	82
c. Ascites.....	83
d. Functions of the stomach and intestinal canal.....	84
c. Alterations of nutrition and other consecutive disorders.....	86
5. Complications.....	88
6. Duration and progress.....	89
7. Modes of termination.....	89
8. Prognosis.....	90
9. Diagnosis.....	90
10. Varieties and illustrative cases.....	91
Simple forms.....	92
Cirrhosis after intermittent fever.....	97
" after syphilis.....	103
Complication with waxy liver.....	105
Influence of chronic peritonitis in giving rise to cirrhosis.....	111
11. Treatment.....	118
Simple induration of the liver.....	121
Cases in illustration.....	123
B. Circumscribed inflammation and abscess of the liver.....	125
1. Anatomical description.....	125
Lesions of other organs in connection with it.....	129
2. Etiology.....	130

	PAGE
a. Contusion.....	180
b. Metastatic hepatitis.....	180
c. Ulceration of the intestine and its relation to hepatitis.....	182
d. Ulceration of the biliary passages.....	188
8. Clinical history and symptoms.....	187
Special symptomatology.....	140
a. Local symptoms.....	140
b. Derangements of the digestive organs.....	141
c. " of the respiration.....	142
d. " of the circulation and fever.....	143
Latent forms of hepatitis.....	143
Symptoms of bursting of abscess through thoracic or abdominal walls.....	144
" " abscess into intestine or bile-ducts.....	145
" " abscess into pelvis of the kidney.....	145
" " into bronchi.....	145
" " into pleura.....	145
" " into pericardium and peritoneum.....	140
Relative frequency of different ways of opening.....	146
4. Modes of termination.....	148
Influence of dysentery.....	149
5. Duration.....	151
6. Complications.....	151
7. Prognosis.....	153
8. Diagnosis.....	153
9. Treatment.....	153
a. General and local abstractions of blood.....	153
b. Purgatives.....	154
c. Emetics.....	155
d. Revulsives.....	155
The treatment of hepatic abscesses and of the diseases to which they give rise.....	156
<i>Syphilitic diseases of the liver. — Hepatitis syphilitica.</i>	159
1. Historical account.....	159
2. Anatomical description.....	160
3. Symptoms and diagnosis.....	162
4. Treatment.....	164
5. Illustrative cases.....	164

CHAPTER IV.

THE WAXY, LARDACEOUS, OR AMYLOID DEGENERATION OF THE LIVER.....	171
1. Historical account.....	171
2. Anatomical description.....	173
3. Etiology.....	175
General circumstances—age, sex, &c.....	175
Predisposing pathological processes.....	176
a. Diseases of the bones.....	176
b. Constitutional syphilis.....	176
c. Cachexia of intermittent fever.....	177
d. Tubercle of lungs and intestines.....	177
e. Unknown causes.....	177
4. Clinical history and symptoms.....	178
5. Duration and progress.....	180
6. Diagnosis.....	181
7. Prognosis.....	181
8. Treatment.....	181
9. Illustrative cases.....	183
A. Syphilitic forms.....	183
B. After diseases of the bones.....	180
C. After intermittent fever.....	181
D. After phthisis pulmonalis.....	186
E. After cancer.....	188