

A DOZEN CASES CLINICAL SURGERY

Published @ 2017 Trieste Publishing Pty Ltd

ISBN 9780649235292

A Dozen Cases Clinical Surgery by Wm. Tod Helmuth

Except for use in any review, the reproduction or utilisation of this work in whole or in part in any form by any electronic, mechanical or other means, now known or hereafter invented, including xerography, photocopying and recording, or in any information storage or retrieval system, is forbidden without the permission of the publisher, Trieste Publishing Pty Ltd, PO Box 1576 Collingwood, Victoria 3066 Australia.

All rights reserved.

Edited by Trieste Publishing Pty Ltd.
Cover @ 2017

This book is sold subject to the condition that it shall not, by way of trade or otherwise, be lent, re-sold, hired out, or otherwise circulated without the publisher's prior consent in any form or binding or cover other than that in which it is published and without a similar condition including this condition being imposed on the subsequent purchaser.

www.triestepublishing.com

WM. TOD HELMUTH

**A DOZEN CASES
CLINICAL SURGERY**

A DOZEN CASES

CLINICAL SURGERY.

106353

BY

WM. TOD HELMUTH, M.D.,

PROF. OF SURGERY IN THE N. Y. HOMOEOPATHIC MEDICAL COLLEGE; ONE OF THE
SURGEONS TO THE WARD'S ISLAND HOM. HOSPITAL, TO THE HAHNEMANN
HOSPITAL, TO THE N. Y. COLLEGE AND HOSPITAL FOR WOMEN;
MEMBER OF THE AM. INST. OF HOMOEOPATHY AND OF THE
SOCIETIES OF MASSACHUSETTS AND RHODE ISLAND;
AUTHOR OF "A SYSTEM OF SURGERY," ETC.

ALBANY:

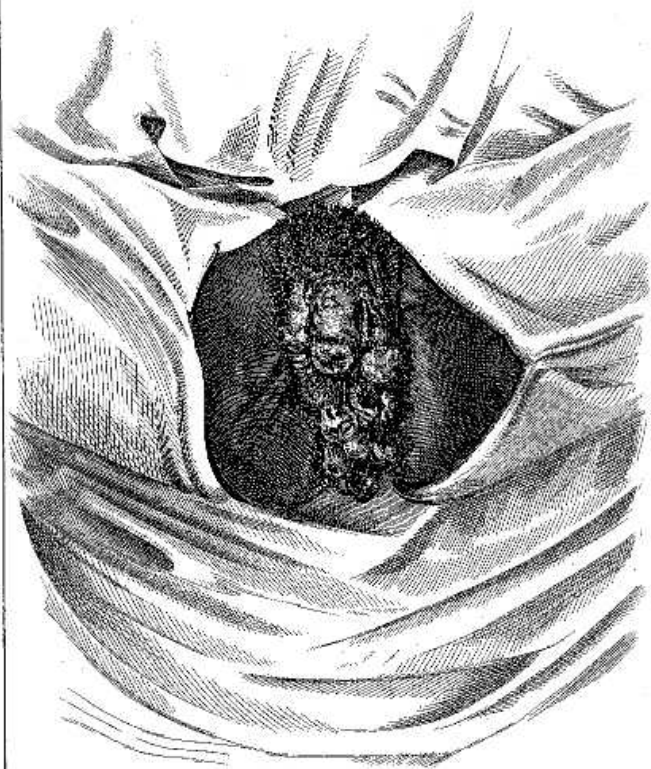
WEED, PARSONS AND COMPANY, PRINTERS.

1876.

CONTENTS.

- Case 1. Hypertrophy of Clitoris—Amputation—cure.
2. Elephantiasis Arabum of the right labium pudendi.
3. Removal of a large "recurrent fibroid" (spindle-shaped sarcoma) from the neck; recurrence in three localities.
4. A case of aneurism of the subclavian and carotid arteries, operated on by ligature of the outer third of the subclavian.
5. Ligature of the common carotid below the omo-hyoid, for erectile tumor of the face—cure.
6. Resection of shoulder—traumatic tetanus—cure.
7. Resection of the os calcaneum—cure.
8. Resection of the entire calcis—amputation of leg—recovery.
9. Amputation of tongue—cure.
10. A successful operation for imperforate rectum.
11. Glass tube in urethra—sloughing of scrotum after removal—cure.
12. Pendulous fatty tumor of the thigh—removal—secondary hemorrhage—cure.

CASE I.



Hypertrophy of Clitoris.
with Condylomata.

SURGICAL CASES

BY

WM. TOD HELMUTH, M. D.

CASE I.

Hypertrophy of the Clitoris—Amputation—Cure.

Although most of our authors on diseases of women mention the fact that the clitoris becomes hypertrophied, very little especial attention or comment is given to the subject, the cases being rare and the reports very meager. When the clitoris begins to exceed its normal dimensions, hermaphroditism, in one of its varieties, may be suspected. As a rule, when this organ is larger than natural the patients are those women who partake largely of the masculine habit, are rather prone to the pursuits and occupations of men, have small breasts and muscular development. In some instances, however, as in the case now under consideration, this organ may acquire the size of the male penis, and indeed, in rare cases, become enormously enlarged. It is said that Paul Lachias, who was physician to Pope Innocent X, records the case of a woman whose clitoris was so large that, when erected during passion, it prevented sexual intercourse. (*Vide* Colombat on Females, p. 84.) Dr. Charles D. Meigs, the editor of Colombat, also relates a case of enormous enlargement of the clitoris, under the care of Dr. Norris, of the Pennsylvania hospital. This case, however, would appear to have been a cyst, for "Dr. Norris plunged a common lancet into the lower end of the tumor and the instrument gave issue to a thick, blackish fluid, the consistence of tar, or thick molasses, and perfectly inodorous." This could scarcely be called a true hypertrophy of tissue, but probably was an extraordinary development of a cyst, such as I have seen in the prepuce of the male.

Mr. Shaw, in the London *Lancet* for 1852, reports a most extraordinary case. The patient was aged fifty-three years and unmarried. He says: "On examination an enormous mass was seen hanging from the pubes, and completely concealing the vulva. The pedicle