THE ANATOMY OF THE BRAIN: A TEXT-BOOK FOR MEDICAL STUDENTS

Published @ 2017 Trieste Publishing Pty Ltd

ISBN 9780649025091

The Anatomy of the Brain: A Text-Book for Medical Students by Richard H. Whitehead

Edited by Trieste Publishing Pty Ltd.
Cover @ 2017

www.triestepublishing.com

RICHARD H. WHITEHEAD

THE ANATOMY OF THE BRAIN: A TEXT-BOOK FOR MEDICAL STUDENTS

Trieste

THE

ANATOMY OF THE BRAIN

A TEXT-BOOK FOR MEDICAL STUDENTS

BY

RICHARD H. WHITEHEAD, M.D.

PROFESSOR OF ANATOMY IN THE UNIVERSITY OF NORTH CAROLINA

Illustrated with Forty-one Engravings

LONDON

HENRY KIMPTON

13, FURNIVAL STREET, HOLBORN, E.C.

1902

PREFACE.

In the preparation of this little book it has been the author's aim to furnish medical students with a clear, accurate, and concise account of the anatomy of the brain, to be used as a guide in their study of that organ. From a work of this character it has been thought best to omit minor details, and to exclude, so far as seemed possible, subjects which are still matters of controversy.

Recognizing the value of a uniform nomenclature, use has been made of the Latin terms adopted and recommended by the German Anatomical Society at its meeting in Basel, to the extent that they have been inserted, parenthetically, after the names commonly employed in this country.

University of North Carolina.

CONTENTS.

CHAPTER I.

CHAPTER II.

CHAPTER III.

CHAPTER IV.

CHAPTER I.

The Divisions of the Encephalon.

As the division of the encephalon, or brain, into its several parts is based upon the embryological development of that organ, it will be necessary to briefly consider the early development of the central nervous system.



Fig. 1.—Transverse section of first-day chick (after Duval). *Ep.*, Epiblast. *N. c.*, Neural canal.

The cerebro-spinal nervous system makes its first appearance as two ridges of epiblast bordering a groove in the median line (Figs. 1 and 2). As these ridges increase in elevation, they soon meet over the back of the groove, which

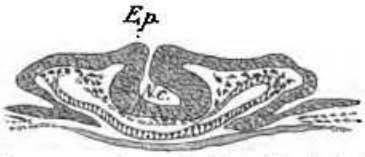

Fig. 2.—Transverse section of first-day chick (after Duval). Reference letters as in Fig. 1.

thus becomes a canal: the neural canal. At this period the embryonic nervous system may be represented as a cylinder whose walls are formed by epithelial cells; in this stage it is called the neural axis. While the great majority of the cells become differentiated into neurones and their supporting